



Dr. Allen L. Johnson, DACVS
Dr. Alexander Z. Aguila, DACVS
Dr. Russell L. Bennett, DACVS
Dr. Kristin Kirkby Shaw, DACVS

Tibial Plateau Leveling Osteotomy (TPLO) Client Handout

How many of these procedures have you performed?

Cranial cruciate ligament (CCL) rupture is the most common orthopedic condition that we treat and occurs in all ages and breeds of dogs. Animal Surgical Clinic of Seattle was one of the first hospitals in the world to perform this surgery, and we have performed in excess of 2800 TPLOs over the last 15 years. In other words, we have as much (or more) experience with this procedure as any clinic out there.

Why did this happen to my dog?

In most dogs, it appears that the CCL degenerates or weakens over time, which predisposes it to rupture with relatively minimal trauma. Some surgeons feel that this degenerative process is a result of an abnormal slope of the top of the tibia (shin bone), which causes chronic stressing of the CCL, but this is yet to be fully understood.

What are the symptoms?

Early signs of CCL stress or partial tear include stiffness or very mild lameness. The dog may show subtle changes in gait, a tendency to shift weight off the affected leg when standing in place, or the inability to sit straight. As the CCL continues to tear further, symptoms increase. A full tear usually results in complete lameness in the affected leg. In some cases, the knee will make a clicking or popping sound as the dog walks. This often indicates damage to the cartilage pads (menisci) within the knee.

How is a diagnosis made?

Diagnosis of a ruptured CCL is done by palpation (feeling the knee) and radiographs (x-rays). Most dogs with a ruptured CCL will have cranial drawer movement on palpation – your surgeon can describe this movement to you. This is the hallmark physical finding. Occasionally, in dogs with a chronic or partial tear of the CCL (or in very tense dogs), cranial drawer movement will not be detected. In these cases, radiographs are very helpful. The radiographic findings associated with a ruptured CCL include osteoarthritis and joint effusion (swelling). The actual ligament cannot be seen on the radiographs.

What is the prognosis for my dog?

The TPLO technique has gained acceptance throughout the country due to consistent reports indicating that dogs treated with TPLO have a better functional outcome and decreased development of osteoarthritis than dogs treated with "traditional" repairs.

The exciting aspect of this technique is the possibility of returning your dog to nearly normal long-term function following CCL rupture (which has not been possible with any of the traditional techniques attempted to date) and the prospect of a reduction in the future progression of arthritis.

Anatomy of the Stifle (Knee)

The cruciate ligaments are important stabilizing elements within the canine stifle joint. There are two cruciate ligaments in the knee, called the cranial and caudal cruciate ligaments. These same structures are present in the human knee, but they are called the anterior and posterior cruciate ligaments. The cranial cruciate ligament (CCL) is commonly injured in both canines and humans (referred to as the ACL in humans).

Two cartilage pads (the medial meniscus and the lateral meniscus) are also found within each knee. Due to anatomical reasons, the medial meniscus is often damaged secondary to the ruptured CCL and resulting joint instability. This by itself frequently results in significant pain and lameness.

What happens when the CCL ruptures?

When the CCL ruptures, stability of the stifle is lost. The slope of the top of the tibia (tibial plateau) and the forces exerted by nearby muscles cause the lower end of the femur (thigh bone) to slide backward and down over the top of the plateau. This means that the top of the tibia thrusts forward with each weight-bearing stride. This is called cranial tibial thrust or cranial drawer movement.

Tibial thrust causes excessive wear of the cartilage on the ends of the bones within the joint, and stretches the surrounding tissues, causing pain. It can also tear the medial meniscus within the stifle.

The Tibial Plateau Leveling Osteotomy (TPLO) can eliminate excessive tibial thrust, thus creating a more functionally stable joint and sound gait.

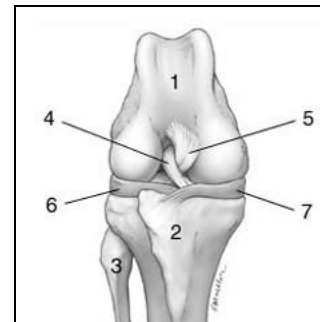
What happens during the surgery?

The surgeon will first examine the inside of the stifle and will remove the torn ends of the CCL. This can be done as a conventional, open surgery or with an arthroscope. Ask your surgeon if you are interested in the arthroscopic option. He will also remove torn portions of the lateral or medial meniscus if a tear is found. Fibrocartilage (scar tissue cartilage) will later fill in this void and replace the function of the damaged meniscus.

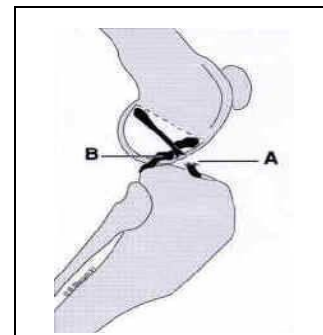
Next, the surgeon will make a curved cut (osteotomy) through the tibia using a specially-designed saw blade. The top portion of the tibia is then rotated a precise number of degrees in order to level the slope of the tibial plateau and prevent the instability and sliding that occurs with a CCL tear.

A bone plate and screws are then placed on the tibia to stabilize it and allow healing to occur. A recent advancement in the TPLO procedure at our clinic is the use of a new plate/screw technology that allows the screw heads to be "locked" into the plate for more stability. The incision is closed with absorbable sutures under the skin and sometimes with skin staples.

A bandage is then placed on the leg from the toe to the top of the leg to reduce swelling. The bandage will be removed before your dog is discharged from the hospital.

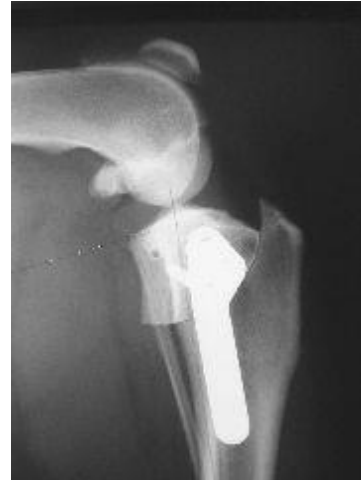
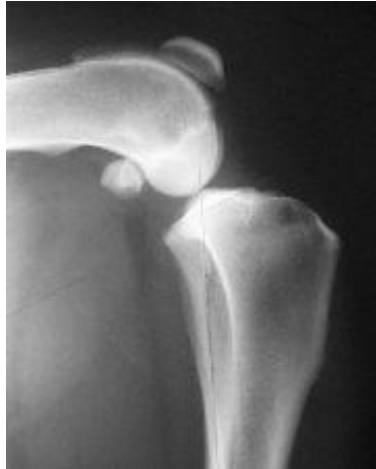
Canine Stifle Joint
1 – Femur
2 – Tibia
3 – Fibula
4 – Cranial Cruciate Ligament
5 – Caudal Cruciate Ligament
6 – Lateral Meniscus
7 – Medial Meniscus



A – Ruptured Cranial Cruciate Ligament
B – Intact Caudal Cruciate Ligament

Pain control for your dog will be addressed throughout the dog's stay at the hospital and the first weeks of recovery at home. All dogs will be given pain medications before, during and after surgery, and the majority will receive take-home pain control medications.



What are the possible complications with this procedure?

As with any surgery requiring general anesthesia, there is an anesthetic risk. Anesthetic complications are rare, however, and risk is minimized by our use of best practices in anesthesia choice and extensive monitoring of your pet by our surgeons, licensed veterinary technicians, and our advanced monitoring equipment.

We see an approximate 3% complication rate with this technique, but most of the complications can be treated successfully, allowing the patient to go on to a full recovery. Complications that have been reported are similar to those seen with other types of orthopedic procedures that utilize bone plates and screws in the area of the upper tibia. They can include: infection, breakage or loosening of the bone plate or screws, delayed healing of the osteotomy site, rupture of the caudal cruciate ligament, inflammation of the patellar tendon, fracture of the tibial tubercle, and post-op meniscal injury. Many of these complications can be the result of too much post-op activity. Occasionally, additional surgery may be needed to solve the problem.